

## Axilla & Brachial Plexus

Dr. Craig Goodmurphy  
Anatomy Guy

---

---

---

---

---

---

---

---

### Major Dissection Objectives

1. Review some of the superficial veins and nerves and extrapolate skin incisions down the arm while sparing the cephalic and basilic veins
2. Secure the upper limb in an abducted position and review the borders of the axilla while reflecting pec major and minor.
3. You may need to remove the middle third of the clavicle with bone cutters or oscillating saw
4. Identify and open the axillary sheath to find the axillary vein and separate it away from the arteries and nerves
5. Once it is mobilized remove smaller veins and reflect the axillary vein medially

---

---

---

---

---

---

---

---

### Major Dissection Objectives Arteries

6. Locate and clean the subclavian artery as it becomes the axillary a. at the first rib.
7. Identifying part 1, 2 and 3 of the axillary artery as they relate to pectoralis minor
8. Identify & clean the thoracoacromial trunk and its branches along with the lateral thoracic artery
9. Clean the subscapular artery and follow it to the circumflex scapular and thoracodorsal branches removing the fat of the region and noting variations and lymph nodes that may be present.
10. Locate the posterior and anterior humeral circumflex arteries and the brachial artery

---

---

---

---

---

---

---

---

### Major Dissection Objectives Nerves

11. Review the parts of the brachial plexus with roots in the scalene gap, trunks superior to the clavicle, divisions posterior to the clavicle, cords and branches inferior to the clavicle.
12. Locate the musculocutaneous nerve laterally as it pierces the coracobrachialis m. then follow it medially to reveal the median and ulnar branches that make the "M"
13. Follow the "M" to the medial and lateral cords and find the posterior cord behind the axillary artery at this point
14. Follow the posterior cord to its radial and axillary branches.

---

---

---

---

---

---

---

---

### Pearls & Problems

- Don't 1. Cut the cephalic vein and avoid circular cuts until superficial structures are identified
- Do 2. Follow each structure and note its relationships to other structures
- Don't 3. Use a scalpel too much
- Do 4. Clean vessels well and remove veins except the superficial ones
- Do 5. Go after specified targets rather than just picking and cleaning random targets

---

---

---

---

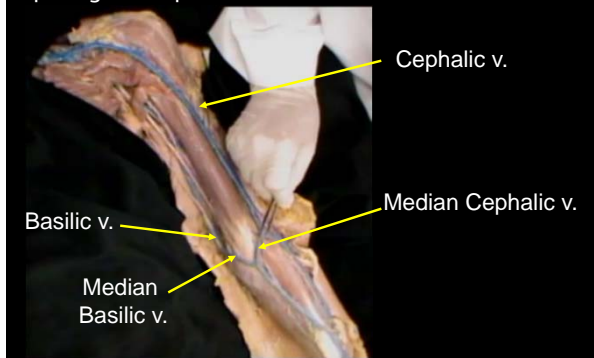
---

---

---

---

Review some of the superficial veins and nerves and extrapolate skin incisions down the arm while sparing the cephalic and basilic veins



---

---

---

---

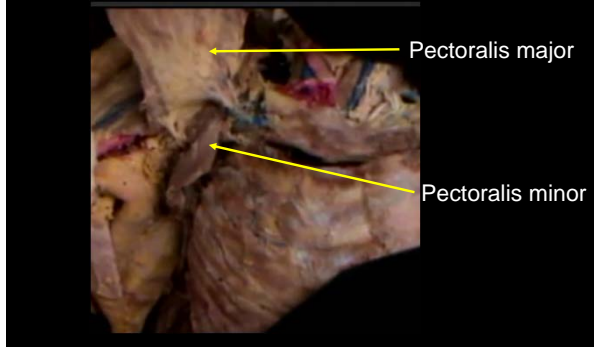
---

---

---

---

Secure the upper limb in an abducted position and review the borders of the axilla while reflecting pec major and minor.



---

---

---

---

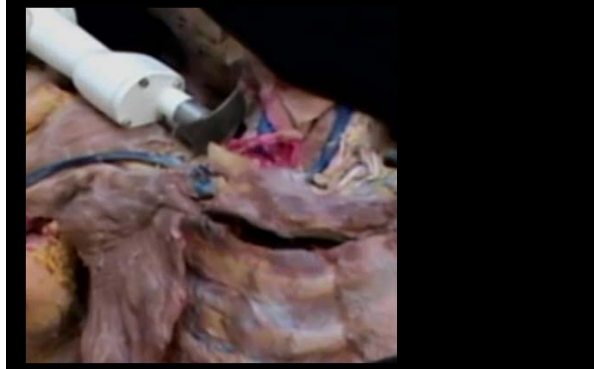---

---

---

---

You may need to remove the middle third of the clavicle with bone cutters or oscillating saw



---

---

---

---

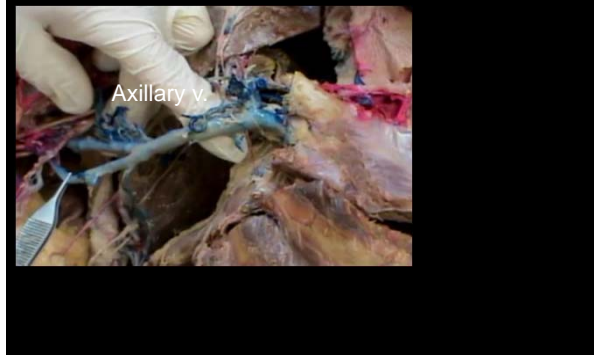---

---

---

---

Identify and open the axillary sheath to find the axillary vein and separate it away from the arteries and nerves



---

---

---

---

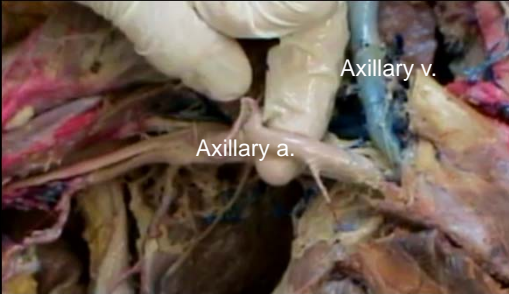
---

---

---

---

Once it is mobilized remove smaller veins and reflect the axillary vein medially




---

---

---

---

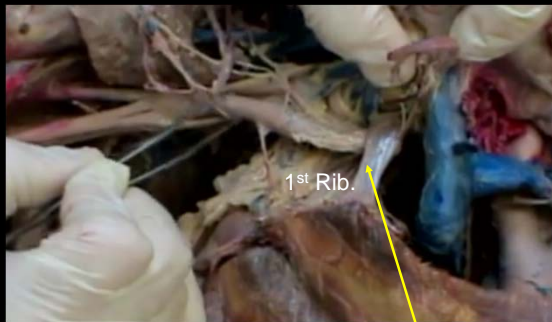
---

---

---

---

Locate and clean the subclavian artery as it becomes the axillary a. at the first rib.




---

---

---

---

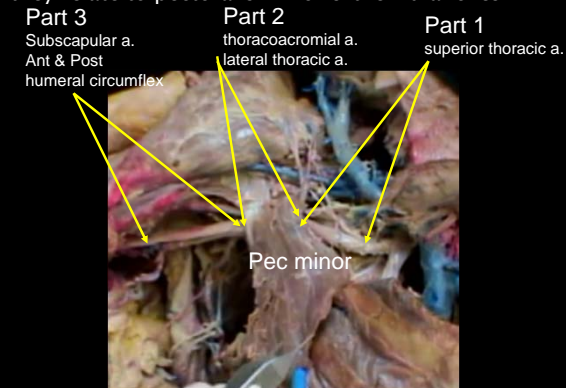
---

---

---

---

Identifying part 1, 2 and 3 of the axillary artery as they relate to pectoralis minor & their branches




---

---

---

---

---


---

---

---

Review the parts of the brachial plexus with roots in the scalene gap, trunks superior to the clavicle, divisions posterior to the clavicle, cords and branches inferior to the clavicle.

**Brachial Plexus**  
**R T D C B**



**5 Roots** - C5, C6, C7, C8, T1  
**3 Trunks** - Upper, Middle, Lower  
**6 Divisions** - 3 Anterior, 3 Posterior  
**3 Cords** - Lateral, Posterior, Medial  
**5 Branches** - Musculocutaneous, Axillary, Radial, Median, Ulnar

---

---

---

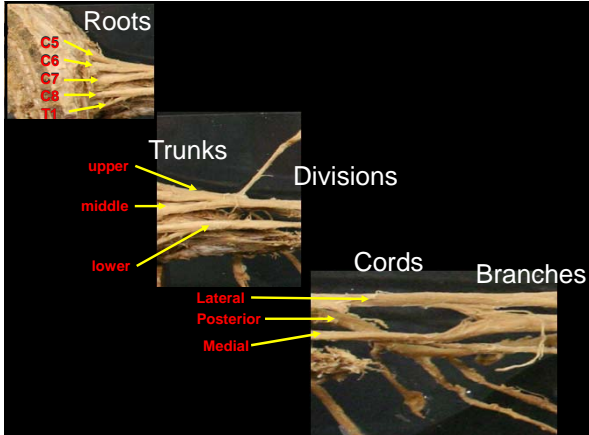
---

---

---

---

---




---

---

---

---

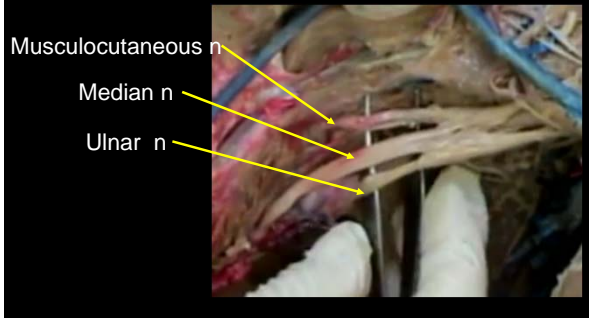
---

---

---

---

Locate the musculocutaneous nerve laterally as it pierces the coracobrachialis m. then follow it medially to reveal the median and ulnar branches that make the "M"




---

---

---

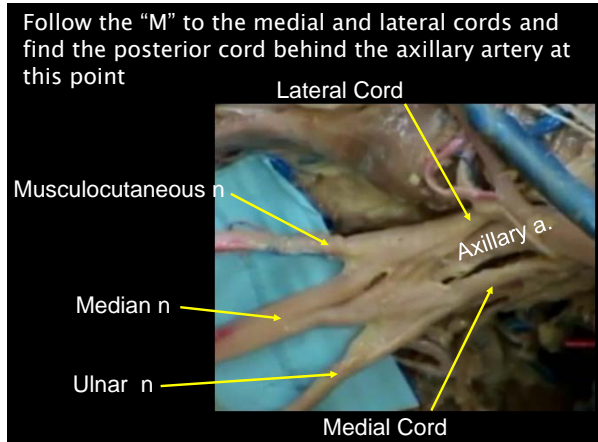
---

---

---

---

---



---

---

---

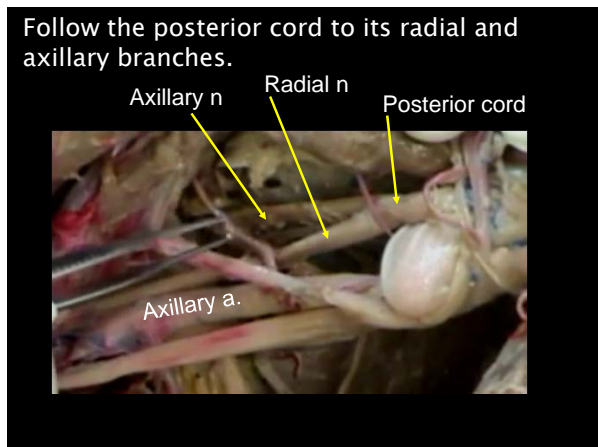
---

---

---

---

---



---

---

---

---

---

---

---

---