

Anterior Triangles of the Neck

Dr. Craig Goodmurphy
Anatomy Guy

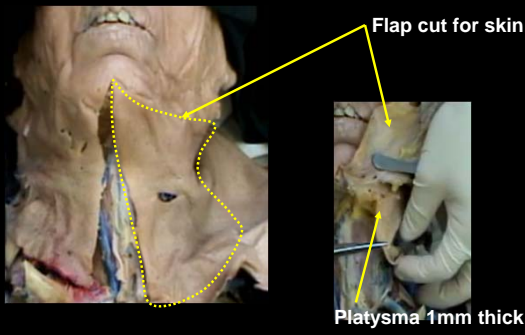
- ### Major Dissection Objectives
1. Reflect skin and platysma being careful to stay just under the skin and just under the platysma at each stage (see post triangle)
 2. Note the superficial veins including the external, anterior and communicating jugulars
 3. Carefully remove any remaining investing fascia and identify the borders of the subtriangles
 4. Trace a branch of the ansa cervicalis back from a strap muscle to find both limbs following the superior to the hypoglossal nerve and the inferior to the cervical plexus
 5. Push the strap muscles off the manubrium, define edges & reflect them superiorly to see the cricothyroid and thyroid gland.

- ### Major Dissection Objectives
6. Clean the carotid sheath sparing the ansa and exposing the vagus nerve
 7. Palpate the hyoid and clean the omohyoid and the bellies of digastric muscles
 8. Locate the submandibular gland and mobilize it without removal
 9. Now clean the common carotid to the bifurcation and identify the branches of the external carotid
 10. Mobilize the common carotid and identify the cervical sympathetic chain and the superior, middle and inferior chain ganglia
 11. Locate the veins and arteries of the thyroid gland as well as the recurrent laryngeal n.

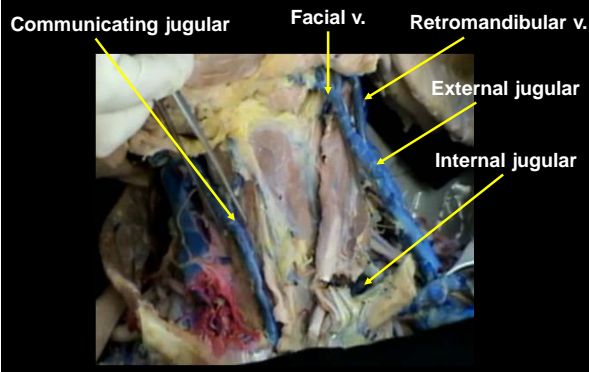
Pearls & Problems

- Don't 1. Dissect the carotid sheath region until you have found the ansa cervicalis
- Do 2. Follow motor branches back from the strap muscles to find the ansa
- Do 3. Mobilize the submandibular gland but be careful not to cut the facial artery
- Do 4. Use the hyoid as a landmark for regionalizing the neck structures
- Don't 5. Cut the thyroid gland yet it will be sectioned later

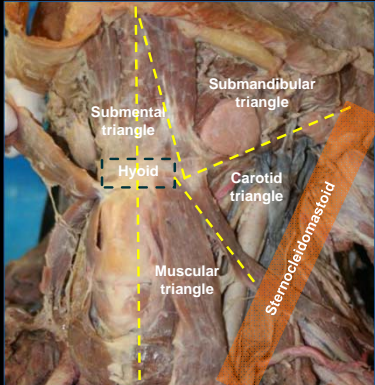
- Reflect skin and platysma being careful to stay just under the skin and just under the platysma at each stage (see post triangle)



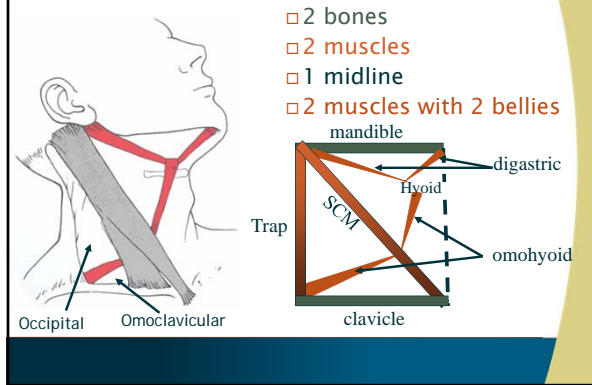
- Note the superficial veins including the external, anterior and communicating jugulars



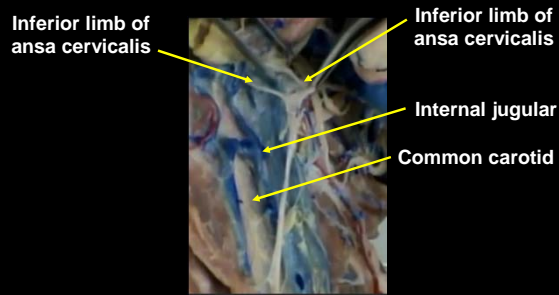
Carefully remove any remaining investing fascia and identify the borders of the subtriangles



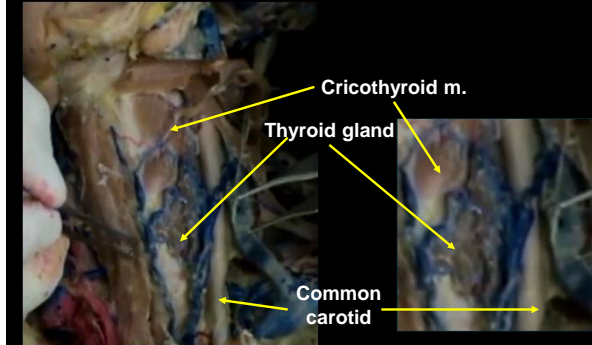
Carefully remove any remaining investing fascia and identify the borders of the subtriangles



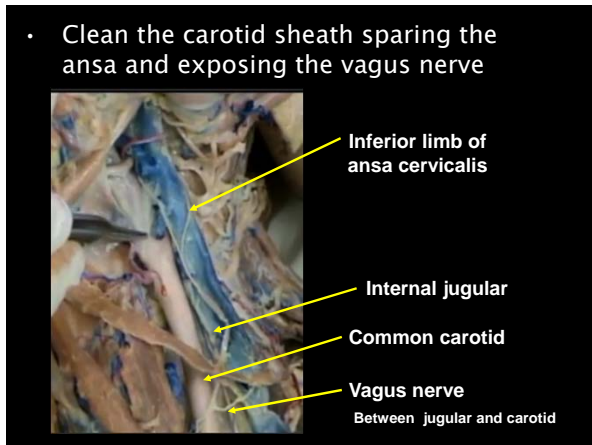
- Trace a branch of the ansa cervicalis back from a strap muscle to find both limbs following the superior to the hypoglossal nerve and the inferior to the cervical plexus



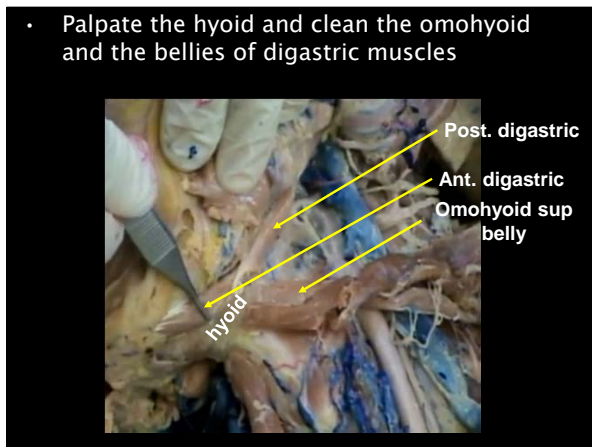
- Push the strap muscles off the manubrium, define edges & reflect them superiorly to see the cricothyroid and thyroid gland.



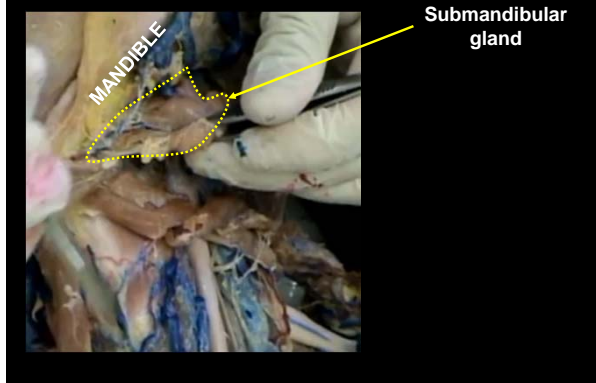
- Clean the carotid sheath sparing the ansa and exposing the vagus nerve



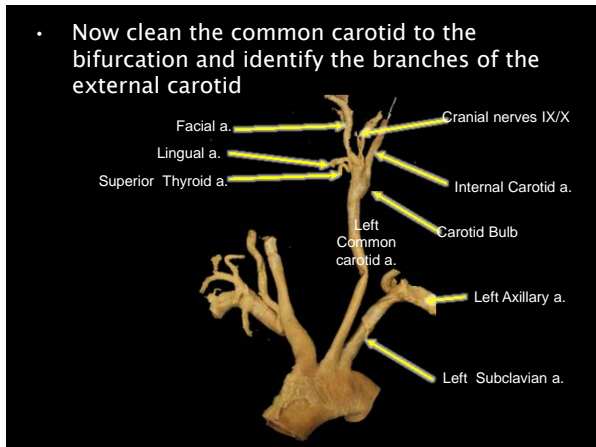
- Palpate the hyoid and clean the omohyoid and the bellies of digastric muscles



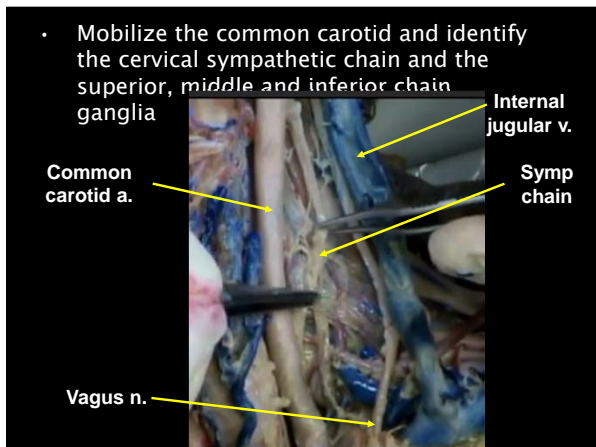
- Locate the submandibular gland and mobilize it without removal



- Now clean the common carotid to the bifurcation and identify the branches of the external carotid



- Mobilize the common carotid and identify the cervical sympathetic chain and the superior, middle and inferior chain ganglia



Anatomy Guy Dissection Sheet
Anterior Triangle of Neck

- Locate the veins and arteries of the thyroid gland as well as the recurrent laryngeal n.

