

Posterior Shoulder

Posterior Shoulder

Dr. Craig Goodmurphy
Anatomy Guy

Major Dissection Objectives

1. Review the scapula and clavicle osteology and the 6 scapulohumeral muscles.
2. Define the deltoid and reflect the posterior segment away from the spine of the scapula to find the axillary nerve and post. circumflex artery & vein.
3. Clean the fascia over the infraspinatus
4. Identify the borders of the teres major, minor and long head of the triceps.
5. Identify the quadrangular, triangular spaces and triangular interval.
6. Reflect the supraspinatus laterally and identify & clean the suprascapular nerve and artery near the tran. scap lig.

Pearls & Problems

Don't 1. Make circular cuts around the arm until the cephalic vein is found and saved.

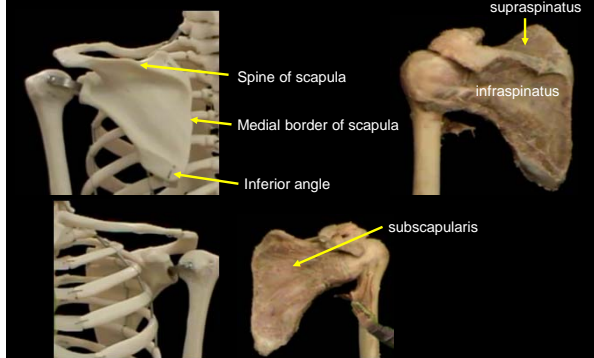
Don't 2. Cut the long head of triceps as you reflect the skin

Do 3. Feel the muscles of teres major and minor to find the separation point prior to defining the edges of each

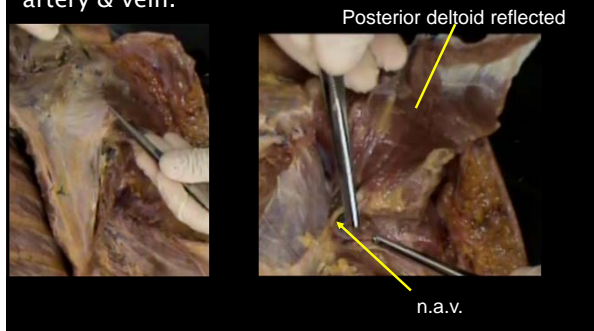
Do 4. Clean the muscles and neurovascular bundles.

Do 5. Follow the latissimus dorsi out laterally to the tendon with fingers before exposing it. Notice it spirals around the teres major before attaching on the anterior humerus.

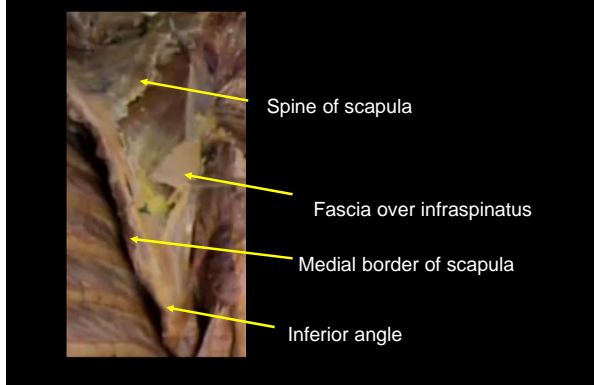
Review the scapula and clavicle osteology and the 6 scapulohumeral muscles.




Define the deltoid and reflect the posterior segment away from the spine of the scapula to find the axillary nerve and post. circumflex artery & vein.



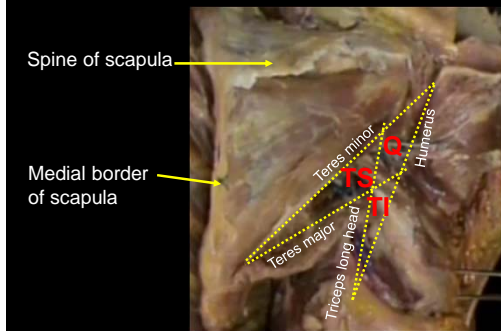
Clean the fascia over the infraspinatus



Identify the borders of the teres major, minor and long head of the triceps.



Identify the quadrangular, triangular spaces and triangular interval.



Reflect the supraspinatus laterally and identify & clean the suprascapular nerve and artery near the transverse scapular lig.

