

Breast & Anterior Shoulder

Dr. Craig Goodmurphy
Anatomy Guy

Major Dissection Objectives

1. Make surface cuts on the thorax and panel the skin only off of one breast and hemisect the other
2. Locate the cephalic vein in the deltopectoral triangle and trace it laterally into the arm to save it
3. Reflect the superficial fascia laterally on both sides exposing the pectoralis major
4. Reflect the pectoralis major laterally to show pectoralis minor and the medial and lateral pectoral nerves
5. Locate the serratus anterior and its associated neurovascular bundle

Pearls & Problems

Don't 1. Go above the clavicle until you have studied the superficial neck adequately.

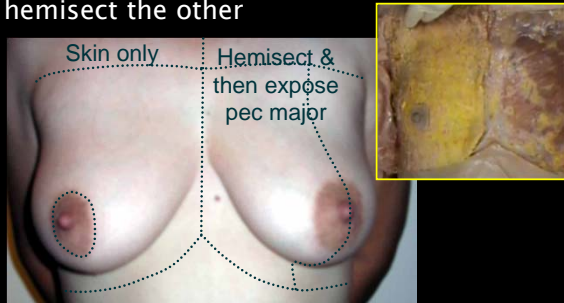
Don't 2. Go too deep in the superior shoulder until the cephalic vein is identified

Don't 3. Cut into breast implants if they are present

Do 4. Look at a dissection of the opposite gender

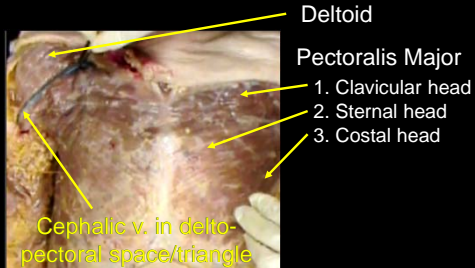
Do 5. Clean the muscles and neurovascular bundles well but don't get into the axilla, neck or abdomen with your cuts

Make surface cuts on the thorax and panel the skin only off of one breast and hemisect the other



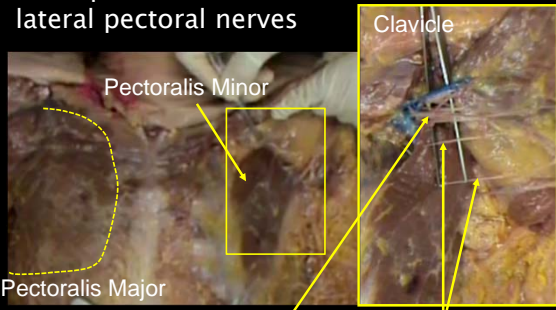
Note the features of the areola and nipple (skip this step on males)
Wikicommons Image:Breast-m-2-200.jpg

Locate the cephalic vein in the delto-pectoral triangle and trace it laterally into the arm to save it



Reflect the superficial fascia laterally on both sides exposing the pectoralis major

Reflect the pectoralis major laterally to show pectoralis minor and the medial and lateral pectoral nerves



Anatomy Guy Dissection Sheet
Anterior Shoulder and Breast

